

Steuphen Roy¹, Chenthilnathan Periasamy², Harvinder Singh³,
Norsalwa Abdul Ghani⁴, Irfan Mohamad¹

Otrzymano: 12.10.2018

Zaakceptowano: 23.05.2019

Opublikowano: 31.07.2019

Naczyniak krwionośny przegrody nosowej – rzadki powód krwawień z nosa u osoby dorosłej

Nasal septal haemangioma: a rare cause of epistaxis in a young adult

¹ Department of Otorhinolaryngology – Head & Neck Surgery, School of Medical Sciences, Universiti Sains Malaysia Health Campus, Kota Bharu, Kelantan, Malaysia

² Department of Otorhinolaryngology, Hospital Taiping, Malaysia

³ Department of Otorhinolaryngology, Hospital Raja Permaisuri Bainun, Ipoh, Perak, Malaysia

⁴ Department of Pathology, Hospital Raja Permaisuri Bainun, Ipoh, Perak, Malaysia

Adres do korespondencji: Irfan Mohamad, Department of Otorhinolaryngology – Head & Neck Surgery, School of Medical Sciences, Universiti Sains Malaysia Health Campus, Kota Bharu, Kelantan, Malaysia, tel.: + 609-7676420, e-mail: irfankb@usm.my

Streszczenie

Naczyniak krwionośny włośniczkowy nosa jest rzadkim zjawiskiem i występuje jako łagodny guz naczyniowy. Etiologia i czynniki ryzyka pozostają nie w pełni rozpoznane; z pewnością stanowi on stan trudny do leczenia. Przedstawiamy przypadek młodego dorosłego mężczyzny, który cierpiał na niedrożność i krwawienia z nosa przez dwa miesiące, a późniejsza diagnoza potwierdziła obecność naczyniaka włośniczkowego przegrody nosowej. Guz był radiologicznie dobrze określony, dlatego przeznosowe endoskopowe wycięcie zmiany przeprowadzono bez przedoperacyjnej embolizacji.

Słowa kluczowe: naczyniak włośniczkowy zrazikowy, naczyniak krwionośny przegrody nosowej, wycięcie endoskopowe

Abstract

Capillary haemangioma of the nose is a rare entity and presents as a benign vascular tumour. Aetiology and risk factors remain uncertain and most certainly, it is a challenging condition to treat. We report a young adult male who presented with a 2-months duration of nasal obstruction and epistaxis and later confirmed to have had nasal septal capillary haemangioma. Transnasal endoscopic excision was done without preoperative embolization as the tumour was radiologically well delineated.

Keywords: lobular capillary haemangioma, nasal septum haemangioma, endoscopic resection

INTRODUCTION

Nasal septal capillary haemangiomas are vascular lesions of relatively serious implications amongst other head and neck haemangiomas as they potentiate nasal bleeding. Presentations are often unremarkably safe for epistaxis and nasal blockage primarily due to the benign nature of these lesions⁽¹⁾.

This lesion is also known as lobular capillary haemangiomas. It occurs less frequently compared to haemangiomas in the oral cavity⁽²⁾. This condition is still misnamed as other known names such as pyogenic granuloma and pregnancy tumour are still being used despite histopathological features of a vascular tumour^(2,3).

Differentiating them from other nasal lesions such as polyps, papillomas, malignant tumours or even rhinolith may significantly help in choosing an appropriate and prompt treatment⁽⁴⁾.

CASE PRESENTATION

A 28-year-old Malay male presented with recurrent unilateral epistaxis for two months. A short duration of upper respiratory tract infection associated with left-sided nasal block and rhinorrhoea for a week worsened with epistaxis compelled him to visit the hospital for a check-up.

The patient has no known comorbidities, no history of trauma and presented no high-risk behaviour. On examination, there was no obvious external nasal deformity seen. No facial swelling or any areas of tenderness were felt.

Nasal endoscopy revealed a left septal mass arising from the anterior part of the nasal septum; it was lobular, pedunculated with extension into nasopharynx (Fig. 1).

He also had the nasal septum deviated to the right. A contrast-enhanced computed tomography (CECT) scan was obtained to further delineate the extent and nature of the mass. CECT of paranasal sinus revealed a well-defined enhancing soft tissue mass arising from the left side of septum involving middle turbinate measuring $2.7 \times 1.3 \times 2.1$ cm (Fig. 2), and the presence of a mass effect on the medial wall of the maxillary sinus without any bony erosion, sclerosis or expansion noted. The mass was not arising from the

pterygopalatine or olfactory fossa. Diagnosis of a vascular mass suggestive of haemangioma was made.

Preoperative embolization was opted out considering the relatively small and well-demarcated mass. Endoscopic transnasal excision of the septal mass was commenced. The surgery comprised the removal of the adjoining septal border and septal spur facilitating an en bloc removal of the mass. Bleeding was minimal as cauterized excision was done using diathermy. Silastic sheets were placed at both sides of the septum. They were removed a week later. The patient showed good recovery during his follow-up review a week later, however, he defaulted the subsequent visits.

A histopathological examination confirmed the diagnosis of septal capillary haemangioma by identification of proliferation of blood vessels lined by a single layer of a benign endothelial layer (Fig. 3).

DISCUSSION

Aetiology and pathogenesis of nasal capillary haemangioma is poorly understood, although many predisposing factors such as trauma, being pregnancy-induced, oral contraceptive pills or even postoperative nasal packing have been documented^(5,6). In our case, a short clinical history with the absence of trauma, childhood anomaly or even an allergic component further adds to the uncertainty of aetiology. Gender and age do depict certain predilections as women in the 3rd decade and children (mainly boys) often present with septal capillary haemangioma^(1,6). Hormonal influence has been implicated in the increased incidence among women^(3,5).

Haemangiomas are benign vascular tumour and are classified as capillary, cavernous and capillary-cavernous (mixed)⁽⁵⁾. Another nomenclature on capillary haemangiomas are infantile and congenital vascular tumours. The former is known to grow rapidly after birth, and undergoes gradual involution as opposed to congenital haemangioma (CH) which presents fully formed at birth. Three subtypes of CH exist; the rapidly involuting congenital haemangioma (RICH), partially involuting congenital haemangioma (PICH) and non-involuting congenital haemangioma (NICH). RICH subtype undergoes rapid involution by the

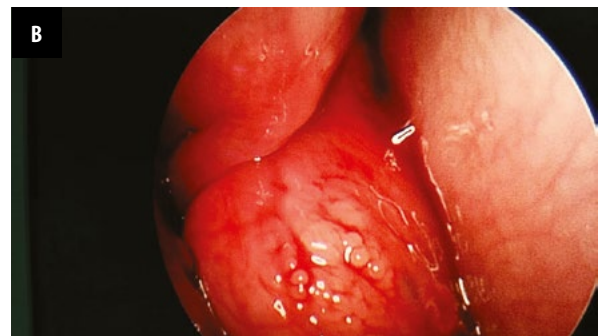
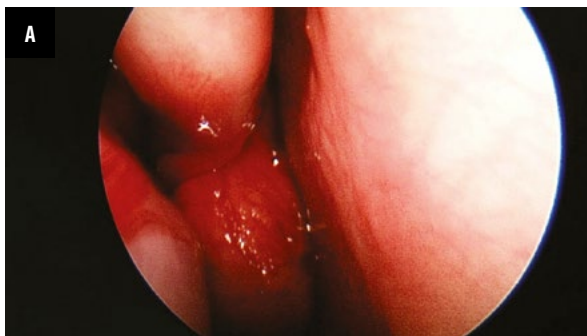

Fig. 1. Intraoperative endoscopic images of the mass in left nasal cavity. A. Lobular reddish smooth-surfaced mass in between septum and lateral wall. B. Lesion seen well demarcated from the middle turbinate superiorly, the septum – medially and the lateral wall – laterally

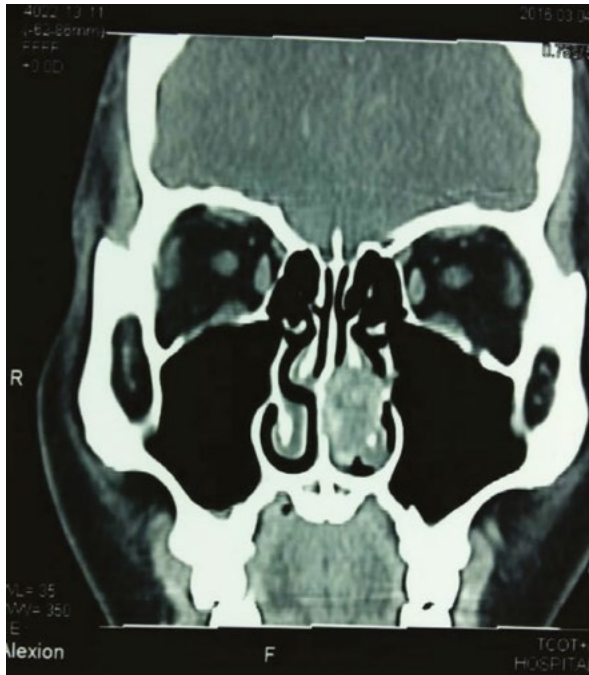

Fig. 2. Coronal CECT paranasal sinus demonstrating lesion in left nasal cavity with no bony erosion

first 2 years, PICH subtype exhibits incomplete regression and occurs over a longer period, whereas the NICH subtype persist into adulthood, which is similar to our case⁽⁷⁻⁹⁾. Glucose transporter 1 (GLUT1), a gene encoded protein which aids transfer of glucose across membrane, is characteristically absent in congenital haemangioma making it a significant immunohistochemical marker⁽¹⁰⁾. The commonest symptoms are nasal block and epistaxis^(1,4,5), as seen in our case. Alongside suggestive symptoms and diagnostic endoscopy, CECT scan of paranasal sinus without biopsy often suffices to aid diagnosis and help determine the disease among various differential diagnosis^(1,4).

On a related note, the vascularity of the lesion best seen with magnetic resonance imaging or even noticeable clinically during endoscopic examination may be contradictory to biopsy due to the risk of torrential bleed. In addition, presence of a well-circumscribed lesion without features of bony erosion, expansion, septal perforation and intracranial extension often suggests a benign nature, hence obviating the need for tissue biopsy prior to surgery.

Macroscopically, the lesions appear small, smooth, lobulated, deep red to reddish-purple, which can be sessile or pedunculated^(1,3). It is commonly located at the Kiesselbach's area at anterior inferior part of septum or posteriorly involving middle turbinate and septum^(2,6,11). Our case presents with the former description i.e. pedunculated reddish lesion arising anteriorly from the septum extending posteriorly to middle turbinate and nasopharynx. Microscopically, submucosal proliferation of blood vessels lined by a benign endothelial cell layer will be seen⁽⁵⁾.

A unilateral mass with epistaxis could be an antrochoanal polyp, angiofibroma, cavernous haemangioma (a form of infantile haemangioma), angiomatous polyps, keratotic fungiform papilloma of septum, hemangiopericytoma or even malignancy^(2,4,12). The aforementioned differentials commonly exhibit features of local aggressiveness such as expansile cavity due to a mass effect, bony erosion, sclerotic bone and even extension intracranially or laterally into pterygopalatine and infratemporal fossa^(2,12).

Nasal septal capillary haemangiomas are best treated surgically for which trans nasal endoscopic resection has gained favour^(4,6). En bloc excision, while maintaining optimal haemostasis precaution, is mandatory as profuse bleeding can be devastating, hence some proponents of preoperative embolization still exist⁽²⁾. However, there is an increasing number of cases that are managed without one depending on the careful preoperative tumour delineation from imaging and on available expertise and experience^(4,6,8). This was supported by a retrospective study in Italy in which surgical

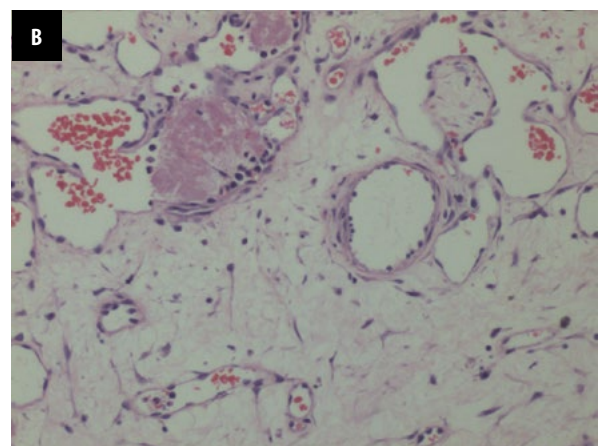
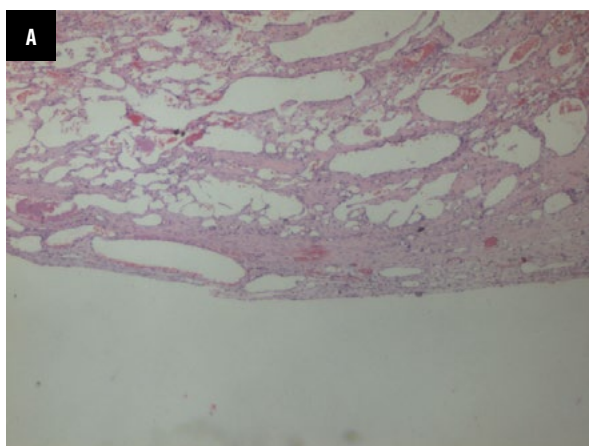


Fig. 3. Proliferation of small blood vessels arranged in lobules; all are lined by a single layer of endothelial cells with uniform nuclei without mitoses or atypia (A: H&E, 4x), Some of the blood vessels are dilated. The background stroma appears oedematous. There is presence of thrombosis in the lumen seen (B: H&E, 20x)

experience favours successful endoscopic surgery involving vascular lesions regardless of size⁽¹³⁾.

An excellent technique with good endoscopic handling skills does provide satisfactory results as in this case the deviated nasal septum, and spur was first addressed to provide better exposure of margins. Besides being cost effective, opting out preoperative embolization also spares the patient from the risks of complications such as periprocedural haemorrhage, ischemia and neurological deficit⁽¹⁴⁾. Nevertheless, a careful selection of cases for endoscopic resection without embolization is still imperative in the management of septal capillary haemangioma. Malignant potential has not been reported although recurrence do occur which warrants regular surveillance follow up^(4,6).

CONCLUSION

The success of proper complete en bloc excision with minimal bleeding without preoperative embolization, as experienced in this case, proves to be affirmative of the current practice in the management of nasal septal capillary haemangioma.

Konflikt interesów

Autorzy nie zgłaszają żadnych finansowych ani osobistych powiązań z innymi osobami lub organizacjami, które mogłyby negatywnie wpłynąć na treść publikacji oraz rościć sobie prawo do tej publikacji.

Piśmiennictwo

1. Nair S, Bahal A, Bhadauria RS: Lobular capillary hemangioma of nasal cavity. *Med J Armed Forces India* 2008; 64: 270–271.
2. Patil P, Singla S, Mane R et al.: Nasal lobular capillary hemangioma. *J Clin Imaging Sci* 2013; 3: 40.
3. Thada SR, Pai KM, Agarwal P: A huge oral pyogenic granuloma with extensive alveolar bone loss and ‘sun-ray’ appearance mimicking a malignant tumour. *BMJ Case Rep* 2014; 2014. pii: bcr2013202367.
4. Kim TH, Lim EJ, Lee JK et al.: Intraosseous hemangioma of the middle turbinate misdiagnosed as a nasal polyp. *Case Rep Otolaryngol* 2014; 2014: 217349.
5. Özkırış M, Aydın R, Seçkin S et al.: A rare cause of pediatric nasal obstruction and epistaxis: nasal septal mixed hemangioma. *Int J Pediatr Otorhinolaryngol Extra* 2013; 8: 104–107.
6. Kovalerchik O, Husain Q, Mirani NM et al.: Endoscopic nonembolized resection of an extensive sinonasal cavernous hemangioma: a case report and literature review. *Allergy Rhinol (Providence)* 2013; 4: e179–e183.
7. Nasser E, Piram M, McCuaig CC et al.: Partially involuting congenital hemangiomas: a report of 8 cases and review of the literature. *J Am Acad Dermatol* 2014; 70: 75–79.
8. Van De Water TR, Staecker H (eds.): *Otolaryngology: Basic Science and Clinical Review*. Thieme Medical Publishers, Inc., New York 2006; 701–702.
9. Pasha R, Golub JS: *Otolaryngology: Head and Neck Surgery. Clinical Reference Guide*. 4th ed., Plural Publishing, San Diego 2014: 537–538.
10. North PE, Waner M, Mizeracki A et al.: GLUT1: a newly discovered immunohistochemical marker for juvenile hemangiomas. *Hum Pathol* 2000; 31: 11–22.
11. Mariño-Sánchez F, Lopez-Chacon M, Jou C et al.: Pediatric intranasal lobular capillary hemangioma: report of two new cases and review of the literature. *Respir Med Case Rep* 2016; 18: 31–34.
12. Kamath PM, Shenoy SV, Kini J et al.: Lobular capillary hemangioma of the nasal septum – a case report. *Egypt J Ear Nose Throat Allied Sci* 2014; 15: 255–257.
13. Goyal S, Jayvardhan G, Goyal S et al.: Angiomatous nasal polyp: clinical diagnostic dilemma. *Int J Cancer Ther Oncol* 2015; 3: 03018.
14. Ogawa AI, Fornazieri MA, da Silva LV et al.: Juvenile angiofibroma: major and minor complications of preoperative embolization. *Rhinology* 2012; 50: 199–202.